

Current concept of laser technology in dentistry – LaserHF®

Autor: Dr. Dragana Gabric Panduric (Dental School university of ZAGREB CROATIA - Department of Oral Surgery)

Laser devices have gained in importance since the eighties and they are often claimed to be omni-use instruments. Though many applications turned out to be impracticable, an unwaning interest in this technique has remained to date. The broad spectrum of applications for the diode laser means that it is now the most widely used device in laser dentistry. Diode lasers offer an interesting – but not unlimited – field of application in modern dentistry including periodontology, endodontics and soft tissue treatment.

LLLT (Low Level Laser Therapy) is the application of red and near infra-red light over injuries or lesions to improve wound and soft tissue healing, reduce inflammation and give relief for both acute and chronic pain. LLLT is used to increase the speed, quality and tensile strength of tissue repair; resolve inflammation and relieve pain (analgesia). The effects of LLLT are photochemical (like photosynthesis in plants). When the correct intensity and treatment times are used, red and near infrared light reduces oxidative stress and increases ATP. This improves cell metabolism and reduce inflammation. Low level laser therapy effects are biochemical and not thermal and cannot cause heating and thereby damage to living tissue. Four distinct effects are known to occur when using low level laser therapy:

- A) Growth factor response within cells and tissue as a result of increased ATP and protein synthesis; improved cell proliferation; change in cell membrane permeability to calcium up-take.
- B) Pain relief as a result of increased endorphin release; increased serotonin; suppression of nociceptor action.
- C) Strengthening the immune system response via increasing levels of lymphocyte activity and through a newly researched mechanism termed photo-modulation of blood.

D) Acupuncture point stimulation. The soft laser offers the dentist several interesting fields of application.

The antimicrobial photodynamic therapy (aPDT) is a non-thermic light-induced inactivation of cells, microorganisms or molecules. „Antimicrobial“ photodynamic therapy targets pathogenic microorganisms. Using a dye, the bacteria that cause infections are stained, sensitized and destroyed following exposure with light of a suitable wavelength and energy density. A decisive role plays the „photosensitizer“, a coloring solution (e.g. Toluidin Blue, Methylene Blue etc.). The oxygen atoms in the color molecules are activated by irradiation of appropriate light. They initiate singlet conditions, which have a toxic effect on the cells. The accent is on LaserHF device, the new instrument in the field of soft tissue surgery. Amazing composition of high frequency, diode laser and therapeutic laser in one unit is intriguing for the clinician. High frequency technology (HF) has been consequently developed since the seventies, with significant advancements over conventional electro surgery. HF is a unspectacular technology, but well known and accepted in surgical applications by most of the dentists. HF is great supplement for laser technology in the oral soft tissue surgery. Laser HF device was used in multiple clinical indications, surgical and therapeutical, at the Department

of Oral surgery, school of Dental Medicine, University of Zagreb during last two years. Wide range of clinical indications including soft tissue oral surgery, endodontic surgery, dental implants exposure in second stage surgery, therapeutic approach of periimplant diseases (conservative and surgical), therapeutic application in cases of intra-oral and labial herpes, aphthae, ulcers and other soft tissue pathological changes. One pilot experimental study was also performed. The aim of the study was to analyse the antimicrobial effectiveness of the Laser HF with the performance: 25ms/s, 2W against intracanal Enterococcus faecalis in vitro using Canal decontamination programme and 975 nm wavelength in the first group. The second group has been done using PDT Laser HF with 2 protocols concerning the power: 50W and 100W. The results were better using higher power of 100W for 60s, so next study evaluating the efficacy of PDT will be performed using 100W. Also, the results with PDT were slightly better than in the 975 nm group, however, statistical analysis has not been done, so nothing can be concluded yet. No side effects or complications of surgery, LLLT or a PDT performed using Laser HF have been found in our clinical research during follow-ups. All patients reported a lack of pain, minimal postoperative discomfort and maximum comfort due to lack of sutures and bleeding.

Case 1

Female patient aged 37 with mucosal fibroma on the right side of the lower lip. The soft tissue surgery was performed using Laser HF, Fibroma removal mode. No side effects or complications after surgery were reported.

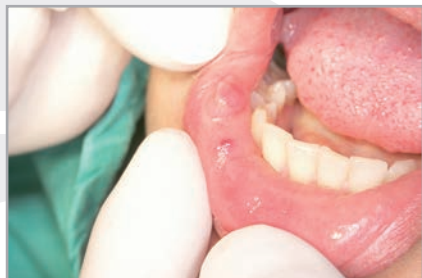

Figure 1. Clinical appearance of the fibroma.

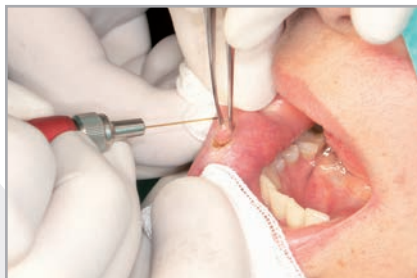

Figure 2. Usage of Laser HF for soft tissue surgical procedure.

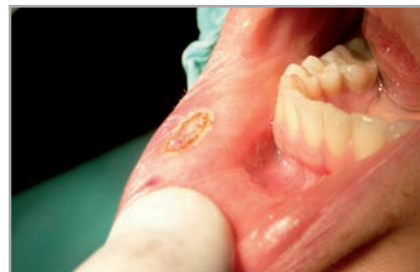

Figure 3. Postsurgical view.

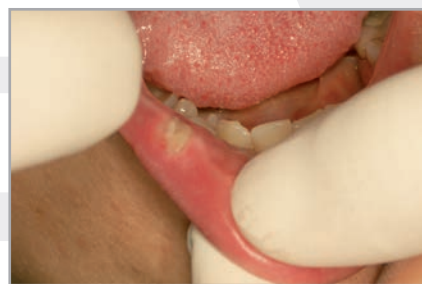

Figure 4. Follow up, 3 days after surgery.

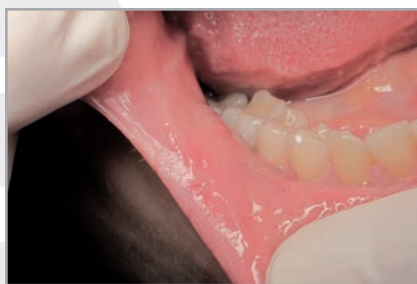

Figure 5. Follow up, 2 weeks after surgery.

Case 2

Male patient aged 31 with mucosal fibroma on the right side in the soft palate. The soft tissue surgery was performed using Laser HF, Fibroma removal mode. No side effects or complications after surgery was reported.

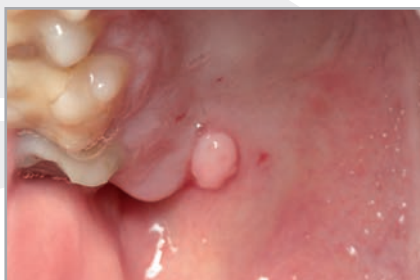

Figure 1. Clinical appearance of the fibroma.

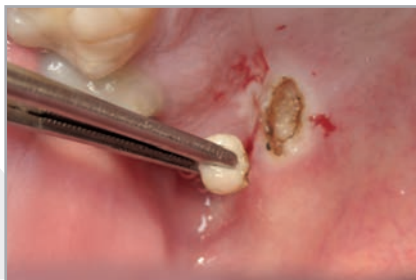

Figure 2. Usage of Laser HF for soft tissue surgical procedure.

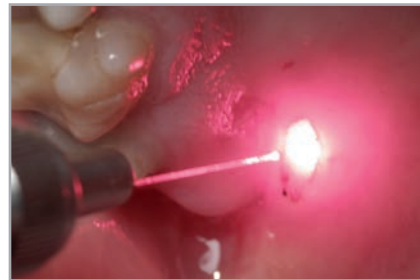

Figure 3. Application of LLLT immediately after surgery.

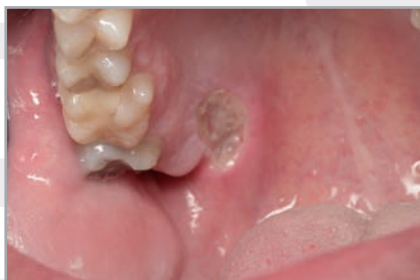

Figure 4. Follow up, 3 days after surgery.

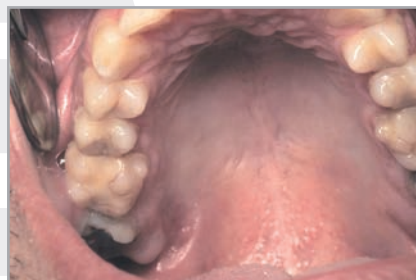

Figure 5. Follow up, 10 days after surgery.

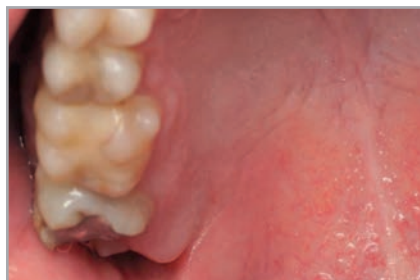

Figure 6. Follow up, 3 weeks after surgery.

Case 3

Female patient aged 59 with palatal fibroepithelial polyp. The soft tissue surgery was performed using Laser HF, Fibroma removal mode. No side effects or complications after surgery was reported.

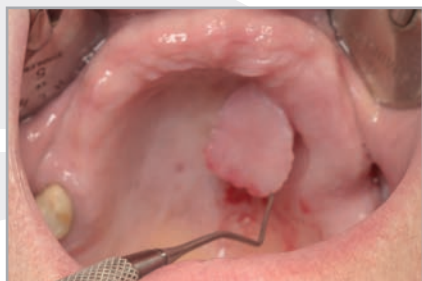
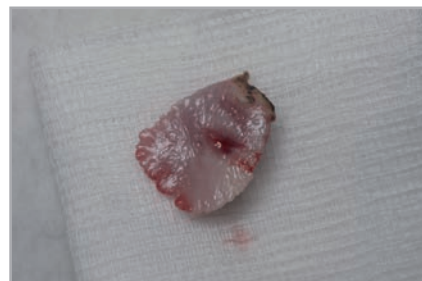
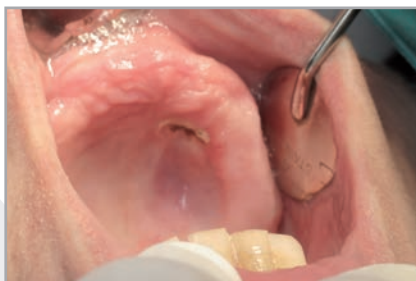Figure 1. Clinical appearance of the palatal fibroepithelial polyp.



Figures 2a & b. Surgical procedure performed using Laser HF.

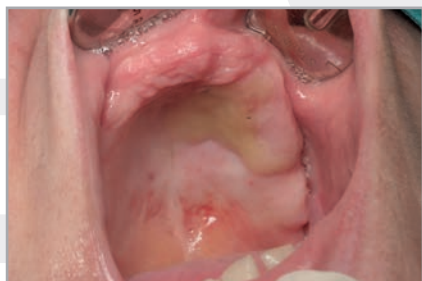

Figure 3. Reso-Pac oral tissue bandage immediately after surgery and LLLT application.

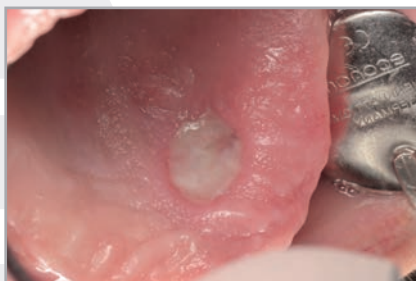

Figure 4. Follow up, 3 days after surgery.

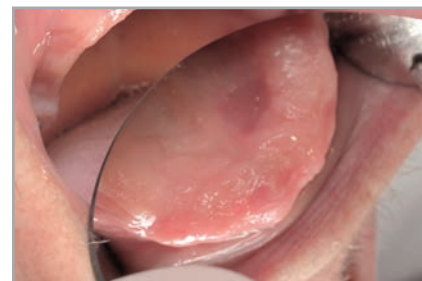

Figure 5. Follow up, 7 days after surgery.

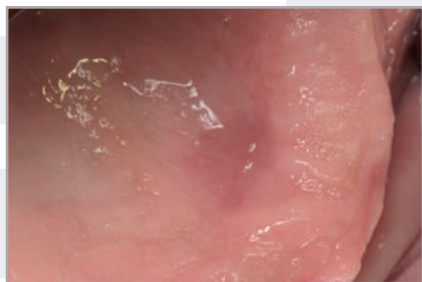

Figure 6. Follow up, 2 weeks after surgery.

Case 4

Male patient aged 62 with epulis fissuratum in the posterior region of left maxilla. The soft tissue surgery was performed using Laser HF, combination of Fibroma removal and Gingivectomy mode, with LLLT application immediately after surgical procedure. Bipolar output was used for haemostasis. No side effects or complications after surgery was reported.

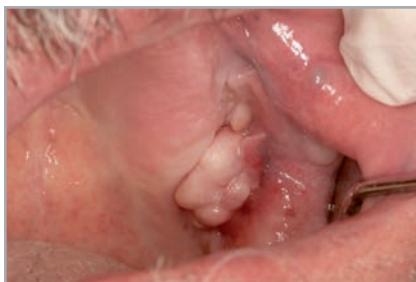

Figure 1. Clinical appearance of the maxillary epulis fissuratum.

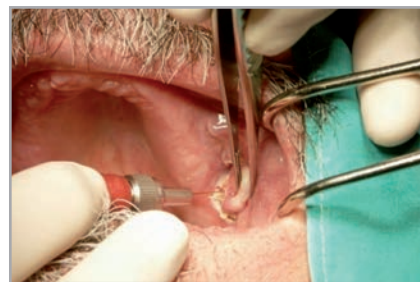

Figure 2. Surgical procedure performed using Laser HF.

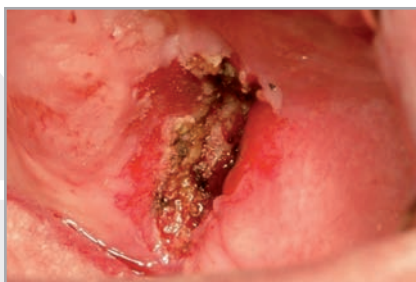

Figure 3. Postsurgical view.

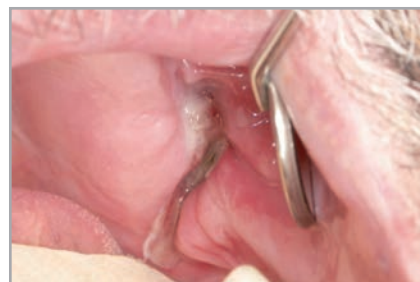
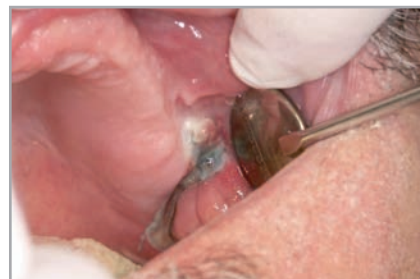
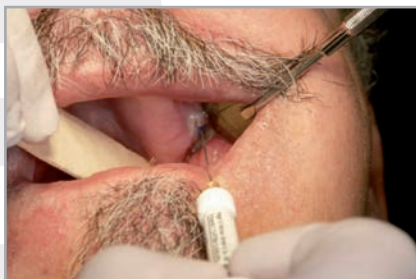
Figure 4. Follow up, 3 days after surgery.



Figures 5a & b. Application of the „photosensitizer“, a coloring solution for aPDT.

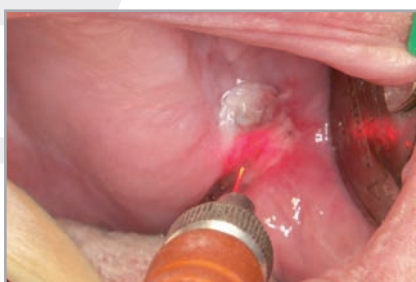

Figure 6. Photodynamic therapy using Laser HF.

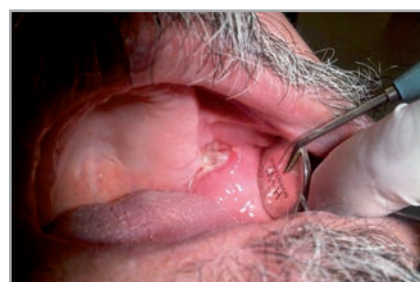

Figure 7. Follow up, one week after surgery.

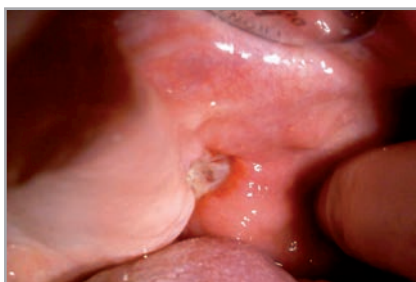

Figure 8. Follow up, 2 weeks after surgery.

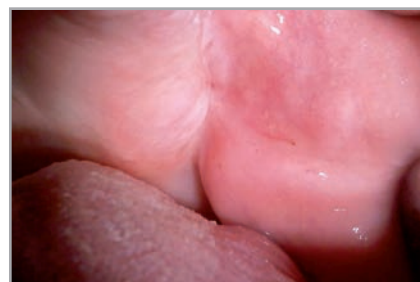
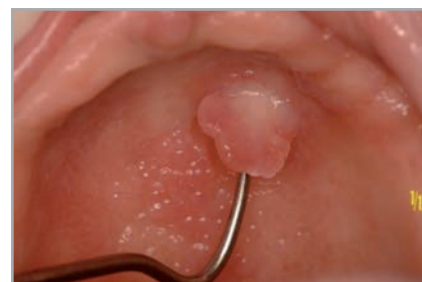
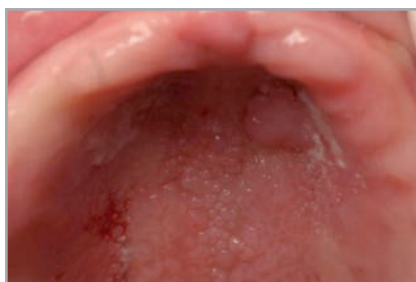Figure 9. Follow up, 5 weeks after surgery.

Case 5

Female patient aged 67 with palatal fibroepithelial polyp and inflammatory papillary hyperplasia of the hard palate. The soft tissue surgery was performed using LaserHF with combination of diode laser using Fibroma removal mode, and high frequency using P2 mode, with LLLT application immediately after surgical procedure. Laser was used for the polyp and HF for the hyperplastic changes of the hard palate using loop. No side effects or complications after surgery was reported.



Figures 1a & b. Clinical appearance of the palatal fibroepithelial polyp and inflammatory papillary hyperplasia of the hard palate

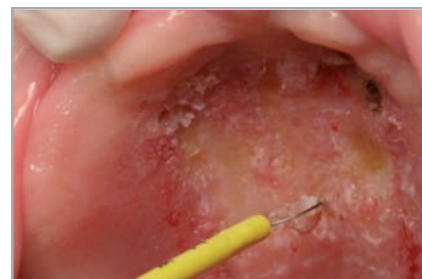
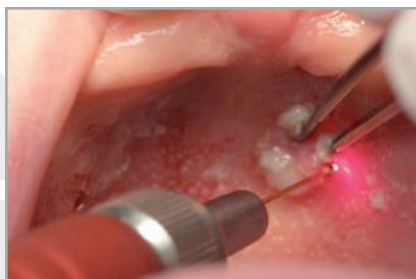
Figure 2. Surgical procedure performed using Laser HF.

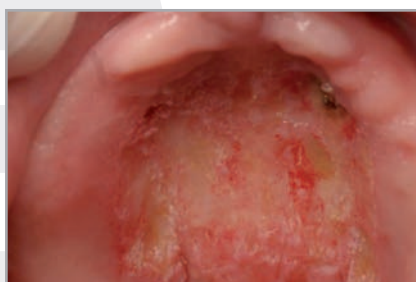

Figure 3. Postsurgical view.

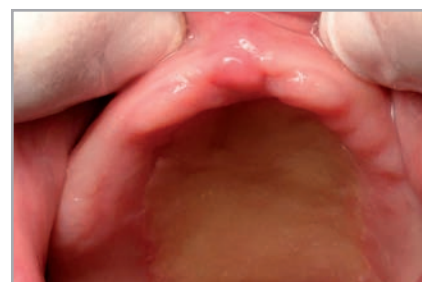

Figure 4. Reso-Pac oral tissue bandage immediately after surgery.

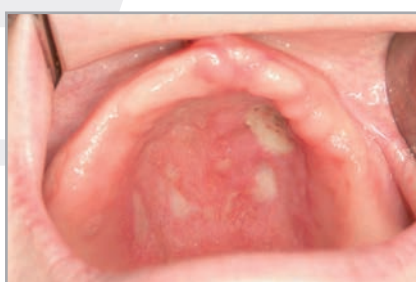

Figure 5. Follow up, one day after surgery.

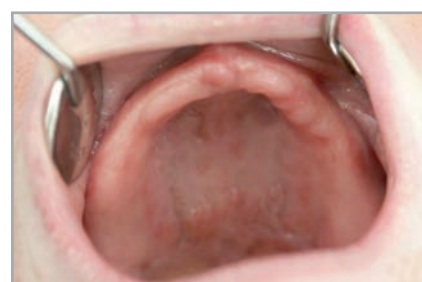

Figure 5. Follow up, one week after surgery.

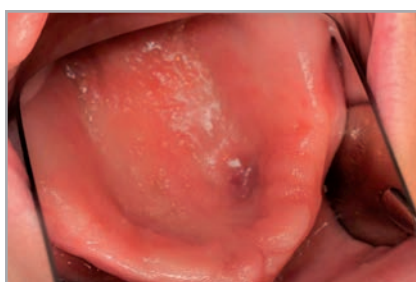

Figure 6. Follow up, 3 weeks after surgery.

Case 6

Female patient aged 34, dental implant exposure in second stage surgery using LaserHF, Implant exposure mode with LLLT application immediately after surgical procedure. No side effects or complications after surgery was reported.

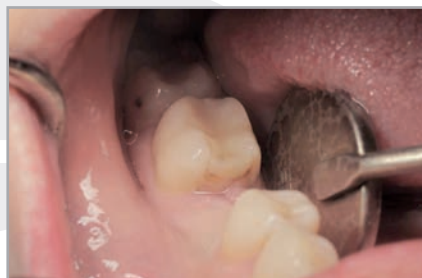


Figure 1. Presurgical clinical view.

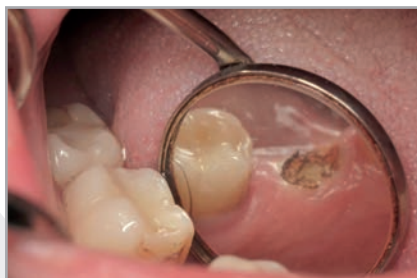

Figure 2. Clinical view during laser surgery.

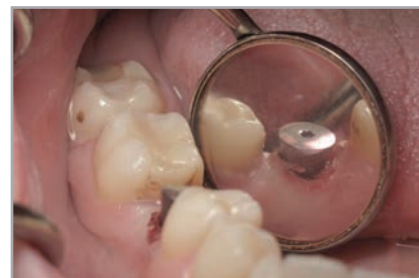

Figure 3. Postsurgical view, after healing abutment placement.



REF 452 462

Case 7

Male patient aged 42 with periimplantitis in the posterior area of the upper jaw, 18 months after loading. Open flap

surgery was done with plastic curette usage and aPDT. No side effects or complications after surgery were reported.


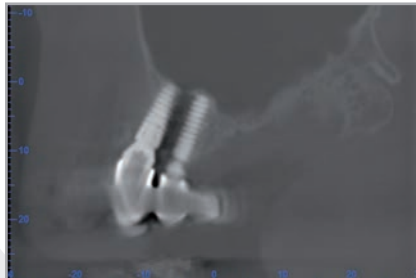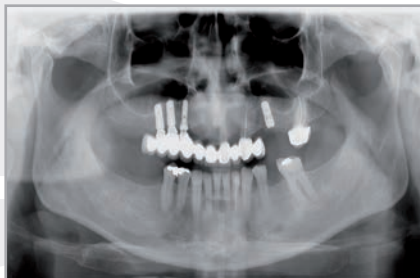


Figure 1. Orthopantomogram.

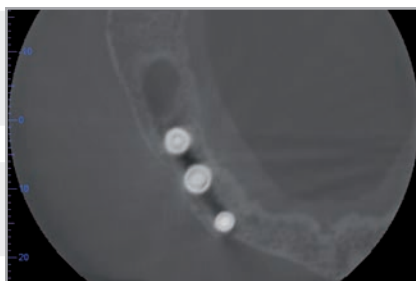
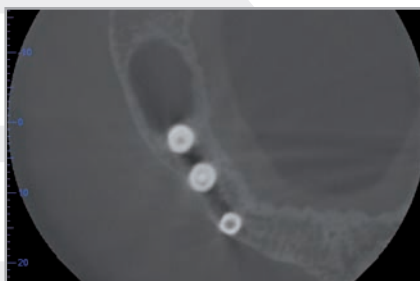

Figure 2. CBCT slices.

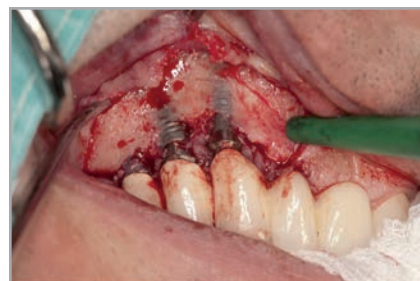

Figure 3. Intraoperative view.

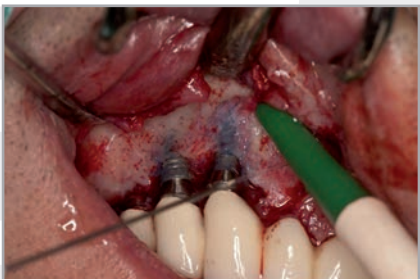

Figure 4. Application of the „photosensitizer“, a coloring solution for aPDT.

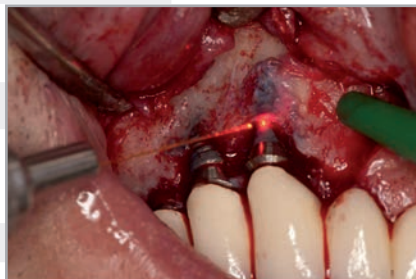


Figure 5. aPDT.

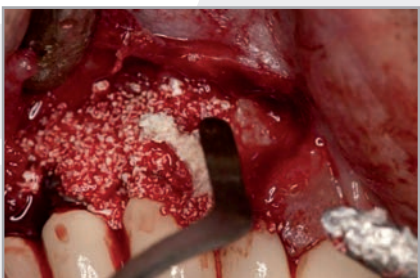

Figure 6. Augmentation with bone substitute material and coverage with resorbable membrane.

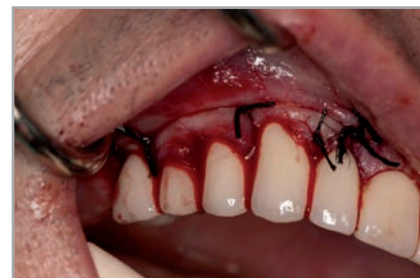
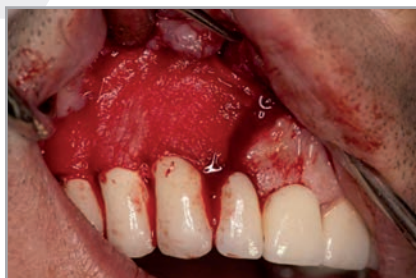
Figure 7. Postsurgical view.