Root-end resection or trephination

A therapy comparison out of the dental practice

Author_ Dr Robert Teeuwen, Germany

_Abstract

The aim of the present study was to evaluate the treatment success of root-end resection compared with that of trephination directly after orthograde root-canal filling of non-vital molars. The survival time, considering extractions and clinical/radiographic success, was tested in 79 teeth with 118 treated roots with a median control time of 58 months. The age of the patient, type of molar and number of appointments were not relevant to the result. The study found that 81 % of the trephined roots and 86.5 % of the resected roots were successful. The success difference was not statistically significant ($p = 0.239$). Regarding failure, both therapies achieved a statistical significance in apical periodontitis lesions of greater than 5 mm in diameter at the beginning of treatment ($p = 0.003$ for root-end resection; $p = 0.043$ for trephination). A statistically significant difference was found between the failure of trephined roots treated by the dental assistants and the failure of those roots treated by the practice owner ($p = 0.044$), possibly because they had less experience than the practice owner did. Overfilled trephined roots showed a tendency to an increased failure rate, but no statistical significance was observed.

_Introduction

The European Society of Endodontology[1] quality guidelines describe the aims of root-end resection (RER) and periapical curettage (PC). RER involves the removal of unfilled root portions and simplifies retrograde RF. With the aid of PC, diseased tissue or foreign bodies are removed from the periapex. The ESE[1] only accepts these two treatments as isolated measures when prior root-canal filling (RF) has been satisfactory. Trephination (TR) of cortical bone after gaining access to the root canal is regarded as an adjuvant treatment to regular endodontic treatment (root-canal therapy—RCT) in case of pain and a blocked root canal. According to several authors various synonyms for bone TR include trepanation, artificial fistulation and aeration (the term "Schröder Lüftung" is used in Germany). According to several authors TR is indicated for emergencies only.[2–8]

Supporters of PC prior to or after RF for systematic treatment of teeth with necrotic pulp can be found in the literature.[9–22] Luebke[23] does not regard removal of the periapical granulation tissue as necessary. According to Lin et al.,[24] partial curettage is adequate because the cause of the granuloma lies in the root canal to be treated. Morse[25] suggests that removal of the pe-

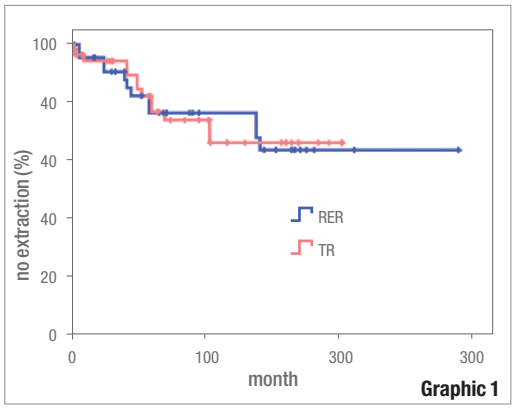

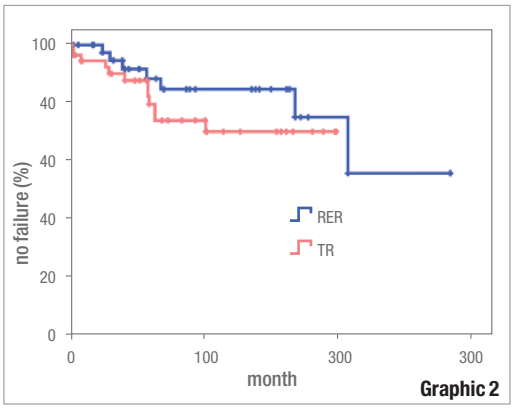

Graphic 1_Kaplan-Meier-Analysis: Survival without extraction root-end-resection vs. trephination.
Graphic 2_Kaplan-Meier-Analysis: Success root-end-resection vs. trephination.

Graphic 3_Kaplan-Meier-Analysis: Root-end-resection success dependent on initial diagnosis.
Graphic 4_Kaplan-Meier-Analysis: Trephination success dependent on initial diagnosis.

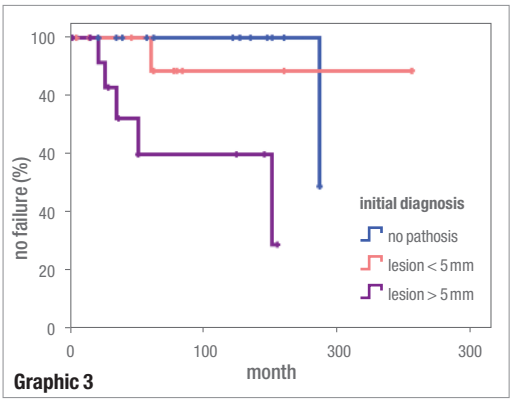

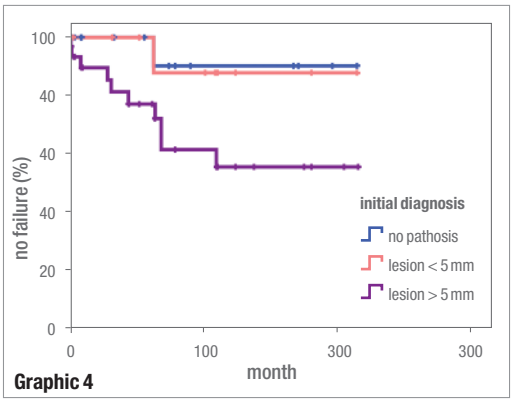

riapical granulation tissue is not necessary for healing. However, he proposes that healing may be accelerated by curettage because the granulation tissue has to be resorbed prior to healing. In Ørstavik's[26] opinion too, removal of the apical lesion does not influence healing. This problem could be resolved with an optimal RCT. According to Velvart,[27] PC is not necessarily essential because the periapical granulation tissue is a response to the canal infection to be treated.

Frank[28] regards PC as being the more extensive treatment compared with TR, but both treatments are nearly symptom-free postoperatively. In cases of persistent pain after RCT, Bender et al.[29] performed PC in anterior teeth and TR in posterior teeth. Trauner[30] performed 64 TRs as the final treatment measure within half a year, and 30 TRs later followed by RER. For Bence,[31] TR is the more conservative method compared with RER. Harrison[32] states: "If definite therapy requires surgery (root-end resection, etc.) there may be a temptation to substitute the definite surgical procedure for the emergency trephination procedure". Already in 1921, Faulhaber and Neumann[33] raised the controversial question of whether to perform RER for endodontic therapy. Sommer et al.[34] too raises the question of whether RER is necessary in the case of apical periodontitis (AP). According to Siskin,[35] resection of a part of the root has no or only a minor influence on the prognosis of the case. In cases of orthograde RF for RCT of a pulp necrosis, Telander[36] and Sargenti[37] almost completely replaced RER with TR with as few appointments as possible.

_Materials and method

Data was collected in the author's practice on RCTs of non-vital molars (necrosis, revision), which were treated by RER or TR following orthograde RF between 1987 and 1999 with the final check-up concluded by 16 March 2012. RCT was executed according to the principles of the simplified Sargenti[37,38] technique. Canal preparation was performed using a reamer with the crown-down technique and no canal rinsing, and the formaldehyde-containing N2 was applied with a lentulo. No gutta-percha point was needed. Contrary to Sargenti, a rubber dam was not used for manual RCT. Isolation with cotton rolls was sufficient.

Apart from one TR case, only the buccal roots were subject to surgical intervention in the maxilla. As with RER, TR was performed by flap. RER was accompanied by PC, but TR was not. In TR, an interradicular bone perforation of the periapex was performed using a turbine drill (Brasseler H1 014). All cases were immediately provided with a filling in both the RER and TR treatment. The basis of evaluation was entries in record cards and single-tooth radiographs.

Roots were grouped as follows based on pre-RCT radiographs:

1. no pathological abnormality detected (NAD) at the apex;
2. apical lesion ≤ 5 mm in diameter; or
3. apical lesion > 5 mm in diameter.

Follow-up x-ray check (min. 1 year post RCT) included diagnostics according to strict criteria with the following differentiation:

_Case 1
Fig. 1a_46 root-canal-treatment in one session: mesial root fracture of reamer: root-end-resection distal root root-canal-filling extruded: trephination (23.09.1997).
Fig. 1b_X-ray post root-end-resection and trephination (23.09.1997).
Fig. 1c_A follow-up (21.12.1999).
Fig. 1d_A follow-up (16.03.2012).

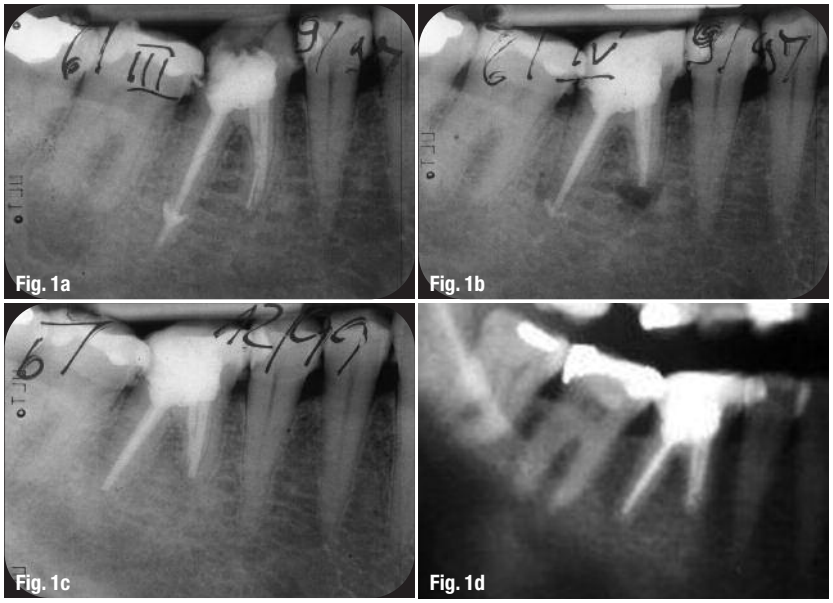

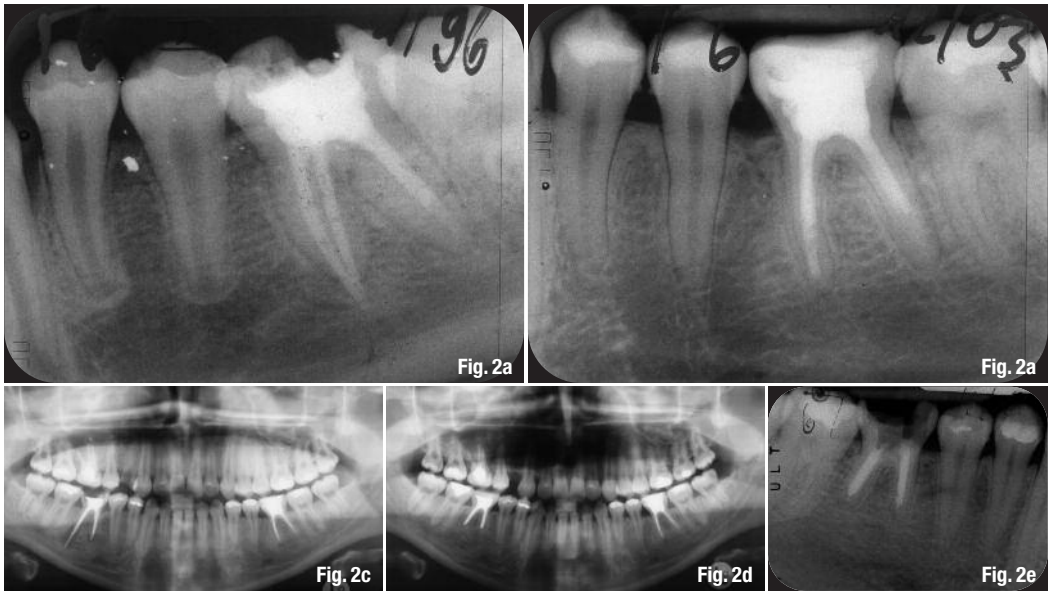

_Case 2

Fig. 2a_RCT was performed in one session in tooth 36. Both roots had been overfilled and were treated with TR (29.01.1996).

Fig. 2b_A follow-up (09.12.2003).

Fig. 2c_36 follow-up 46 root-canal-treatment in 1 session. Both roots with lesion, distal root tremendous overfill, both roots root-end-resection (09.04.2002).

Fig. 2d_A follow-up showing teeth 36 and 46 healed (09.03.2004).

Fig. 2e_A follow-up of tooth 46 (29.04.2011).

1. NAD at the apex;
2. problematic/apex doubtful; or
3. pathological apex: persistent, reduced, or newly developed lesion.

The instruments used for diagnosis were 2 magnifying glasses, one with 2x and one with 7x (incl. mm scale) magnification. Diagnosis was performed by the author (40 years of practical experience) and separately by a colleague (30 years of practical experience) with significant experience as a court-appointed expert who had never before worked according to the a.m. RCT method. If the respective radiographic diagnoses did not correspond, the worst was chosen for evaluation. In case of a discrepancy between diagnosis 1 and diagnosis 3, a mid-way diagnosis 2 was made.

The last patient appointment in the practice without reintervention at the tooth, root or RF was used for the end of the survival time. So the date of a reintervention, such as a tooth extraction or RER, was considered the last day in function.

Statistical analysis was performed in SPSS (version 19.0, SPSS). The data was analysed using the chi-squared test and the Fisher exact test. A two-page significance check was performed for all tests based on a statistically significant p-value of < 0.05. Determination of survival times was done using the Kaplan–Meier estimate. The log-rank test was used to compare the survival times.

_Results

The median age of the patients was 27.39 years. The mean value was 30.99 years (min. 11, max. 63 years). The treatment of 79 teeth was finished in one appointment for 70.9%—among these, 13 teeth were pretreated alio loco. Treatments that needed more than one appointment were finished within 21 days. The median follow-up time of the treated roots amounted to 58.43 months, and the mean follow-up time was 77.45 months. All treated teeth were available for clinical follow-up for a maximum of 290 months in the case of RER and for a maximum of 199 months in the case of TR. Two molars with altogether three TR roots did not undergo follow-up. RER was done in 34 non-vital molars (necrosis, revision) with 52 roots—22 (64.7%) maxillary first molars, nine (26.5%) mandibular first molars and three (8.82%) mandibular second molars. TR was performed in 45 molars with 66 roots—25 (56%) mandibular first molars, 12 (27%) maxillary first molars, five (11.11%) mandibular second molars, two (4.44%) mandibular third molars, and one (2.22%) maxillary second molar.

_Case 3

Fig. 3a_RCT was performed in one session in tooth 46. RER was performed in the mesial root and TR in the distal root (13.06.1997).

Fig. 3b_A radiograph post-RER and TR (13.06.1997).

Fig. 3c_A follow-up (18.12.1998).

Fig. 3d_A follow-up (13.12.2011).

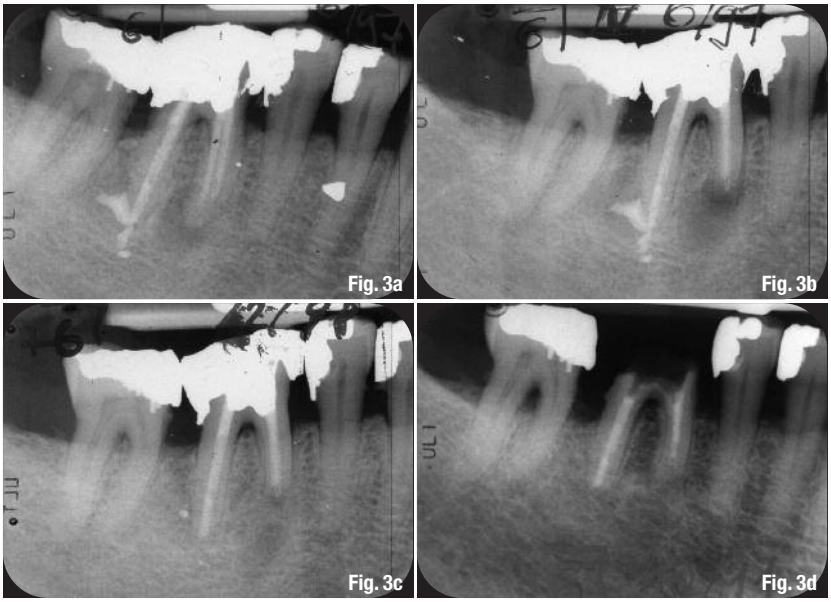

_Case 4

Fig. 4a_Tooth 38 was treated conservatively in one session with RF (02.12.1993).

Fig. 4b_Pain: trephination (03.12.1993).

Fig. 4c_A follow-up (20.09.2000).


Fig. 4a

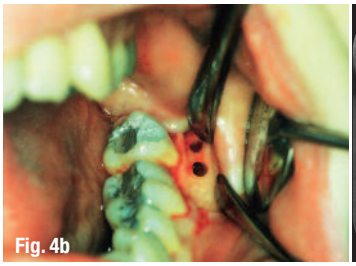
Fig. 4b

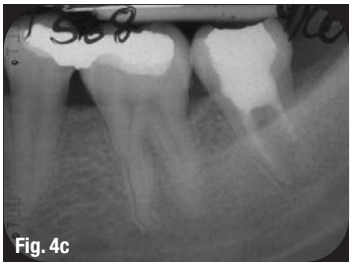
Fig. 4c

RER was most frequently performed in the mesiobuccal root of the maxillary first molars, with 19 cases (37 %), and TR was most frequently performed in the distal root of the mandibular first molars, with 23 cases (35 %). Six teeth were treated with RER or TR at different roots during the same appointment: five mandibular first molars with RER of the mesial root and TR of the distal root (four with RF +3, one with RF -1), as well as one maxillary first molar with RER of the mesial root and TR of the distobuccal root. In one maxillary first molar, the mesiobuccal root was hemisected and the poorly filled distobuccal root was resected. Hemisection of the distobuccal root of another maxillary first molar was performed with TR of the palatal root through the alveolus of the removed root.

During the follow-up period, eight RER teeth (23.5 %) with 12 roots (23.1 %) were extracted—three of which exhibited radiographic failure—as well as ten TR teeth (23.3 %) with 13 roots (20.6 %)—two of which exhibited radiographic failure and one extraction due to acute exacerbation. Thus, 76.9 % of the RER roots and 80.3 % of the TR roots survived the follow-up period without extraction. Survival development is shown in Figure 1. The survival difference of $p = 0.981$ was not statistically significant. However, a statistically significant difference between RER and TR of $p = 0.005$ regarding extraction frequency of teeth was found in relation to the initial diagnosis of an AP lesion > 5 mm versus all other diagnoses. Of teeth diagnosed with this more progressed apical lesion, 58 % survived after five years and 52.2 % after ten years. In the case of other diagnoses, 89.6 % and 85.4 % of the teeth survived after five and ten years, respectively.

A fractured instrument led to immediate RER six times. Despite RER, the fractured file remained in the canal for another five and 12 years, respectively, without disadvantage in these cases. In the TR roots, an instrument had fractured in the overfilled mesial root of a mandibular first molar and the tooth was extracted after four years with NAD at the apex clinically or radiographically. Three TR roots (two teeth) had to be resected seven and 58 months post-TR, respectively, owing to failure. Per definitionem, the RER data meant the end of the survival time although the respective teeth fulfilled their function for another 13 respectively 10 years.

Half of the follow-up radiographs dated from more than 49 months post-RER and more than 62 months post-TR. The two radiograph evaluators made the same diagnoses, 65 % in RER and 59 % in TR. Forty-three (36.4 %) of the 118 treated roots were diagnosed as NAD at the apex radiographically. Aside from one case, AP as initial diagnosis was proved to result in later radiographic failure. A differentiation of RER and TR showed seven roots each as radiographic failures, that is, 17.1 % in RER and 15.9 % in TR. Another TR tooth with two treated roots with a radiographic diagnosis of a problematic/insecure apex was added to the failures. This was a mandibular molar whose roots had been resected 58 months after TR without RF revision. Acute exacerbations were not observed after RER, but were observed three times after TR in teeth with an initial large AP lesion and anamnestic pathology. One of these teeth was extracted after six days, a second one resected after 21 days, and the third one underwent RER with retrograde RF after seven months. A mandibular first molar that had to be re-trephined after 16 days owing to persistent pain was not classified as a failure but as a complication of TR. This tooth remained under control without any symptoms for another six years. Taking the two TR patients who did not return for treatment into account, TR had a total failure rate (radiographically and clinically) of 23.3 % in 43 treated teeth with ten failures and 19 % in treated roots with 12 failures. Thus, after a post-operative control phase, successful treatments were as follows: 27 teeth

_Case 5

Fig. 5a_RCT was performed in one session in tooth 46. Both roots had lesions pre-RCT.

Fig. 5b_The mesial root was underfilled and the distal root was overfilled post-RF. RER was performed with N2 in the mesial root post-RF and TR was performed in the distal root.

Fig. 5c_Flap, mesial root already resected, distal root trephined.

Fig. 5d_Post root-end-resection and post trephination (Figs. 5a–d: 15.05.1994).

Fig. 5e_A follow-up (20.10.2007).

Fig. 5f_A follow-up (17.11.2011).


Fig. 5a


Fig. 5b


Fig. 5c


Fig. 5d


Fig. 5e


Fig. 5f

(79.4 %) with 45 roots (86.5 %) for RER, and 33 teeth (76.7 %) with 51 roots (81 %) for TR. A statistically significant difference in success between both therapy forms was not found ($p = 0.239$; Fig. 2). Such a difference between RER and TR was only found in relation to the initial diagnosis. During the follow-up phase a therapy success rate of 70.6 % after RER for an AP lesion > 5 mm was achieved compared with 94.3 % for smaller lesions or NAD at the apex ($p = 0.003$), and of 67.7 % compared with 93.8 % after TR ($p = 0.043$; Figs. 3 & 4).

The results showed no statistically significant preference of a post-operative AP lesion for certain tooth locations when comparing the most frequently treated tooth locations—16/26 in RER and 36/46 in TR—with the sum of the remaining treated tooth locations ($p = 0.44$ for RER compared with $p = 0.746$ for TR). There was also no statistically significant difference of failures depending on the patient's age based on a median age of 27.39 years ($p = 0.497$ for RER compared with $p = 0.705$ for TR). Five of the seven RER failures and nine of the ten TR failures were ascribed to an anamnestic pathology. The number of appointments—one appointment versus more than one appointment—had no statistically significant influence on the failure rate ($p = 0.779$ for RER compared with $p = 0.672$ for TR). Nine of the 39 overfilled roots of the TR group led to failure (23.1 %), compared with three of the 24 non-overfilled roots (12.5 %). This difference ($p = 0.371$) was not statistically significant. The 14 poorly filled RER roots and the ten insufficiently filled TR roots had two failures each. In revision treatments, there was only one failure in a TR case. A statistically significant difference in failure of $p = 0.044$ was observed regarding personnel involved in treating trephinated teeth (13.5 % for the author compared with 26.9 % for the assistants). The results are shown in Tables 1 and 2.

_Discussion

Regarding treatment success, the present study combined the follow-up X-ray pictures to be interpreted with the clinical situation, which may lead to a less positive result compared with evaluation of radiographs only.[39] The individually treated roots were evaluated radiographically, which showed better results than evaluation of tooth units.[39] This finding corroborates that of Swartz et al,[40] whose study of 1,007 teeth with 1,770 canals found a failure rate of 12.21 % of teeth and 10.43 % of roots after one–ten years. In this study, the development of the tooth units excluding reinterventions (extraction, RER) resp. last check-up was followed in parallel to healing success. Ultimately, it is essential for the patient that a root-treated tooth remain in function in the mouth and asymptomatic for as long as possible.[41] Torabinejad et al.[41] report a healing success rate of 75 % in their systematic RER review. The authors noticed a functional success rate of 84.4 %. Friedman and Mor[42] determined a highly variable healing rate of teeth with AP after RER of 37–85 % (average of 70 %), as well as a functional success rate of 86–92 %. Based on their meta-analysis, Ng et al.[43] concluded that with reference to extractions survival rates exceed healing rates. Furthermore, they state that no studies thus far have analysed the survival and healing rates for the same patient. The present study has attempted to do so.

A disadvantage of this study is the low number of cases (79 molars with 118 treated roots), which relativises the statistical relevance of the results. This low number of cases means that only significant percentage differences indicate statistical significance. According to Trope et al.,[44] a minimum of 350 cases is needed to render a 10 % difference between two subjects statistically relevant. Lewsey et al.[45] concluded from their meta-analysis that studies with a higher

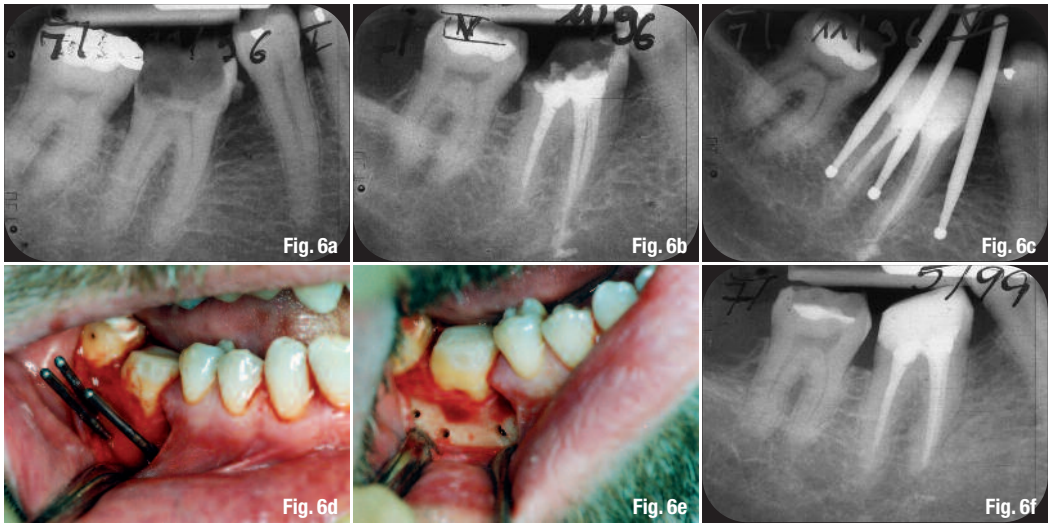

_Case 6
Fig. 6a_47 root-canal-treatment in one session ante root-canal-treatment.
Fig. 6b_TR performed post RF.
Fig. 6c_TR drill *in situ*.
Fig. 6d_TR drill *in situ*.
Fig. 6e_Three TR holes (Figs. 6a–e: 22.11.1996).
Fig. 6f_A follow-up (27.05.1999).

		RER		TR	
		n	%	*n*	%
Treated teeth		**34**	100	**45**	100
Patient	Male	17	50	26	57.8
	Female	17	50	19	42.2
Treatment	Author	24	70.6	26	57.8
	Assistant	10	29.4	19	42.2
Symptomatic pre-RCT		26	76.5	37	82.2
Sessions	1	21	61.8	35	77.8
	>1	13	38.2	10	22.2
Treated roots		**52**	100	**66**	100
Necrosis		48	92.3	59	89.4
Retreatment		4	7.7	7	10.6
Location	17/27	0	0	1	1.5
	16/26	36	69.2	17	25.8
	36/46	11	21.1	36	54.5
	37/47	5	9.6	9	13.6
	38/48	0	0	3	4.5
AP lesion pre-RCT	None	19	36.5	24	36.4
	< 5 mm	16	30.8	11	16.7
	≥ 5 mm	17	32.7	31	47
RF length	Short of apex	25	48.1	13	19.7
	-1	10	19.2	13	19.7
	Overfilled	17	32.7	40	60.6
RF quality	Well condensed	38	73.1	56	84.8
	Poorly condensed	14	26.9	10	15.2
Radiograph more than one year later		41	78.8	44	66.7
Radiographic failure	Sure	7	17.1	7	15.9
	Sure + questionable	7	17.1	9	20.5
	16/26	6		1	
	36/46	1		6	
Table 1	37/47	0		2	

Table 1_Comparison of RER vs. TR in non-vital molars.

number of participants report more success rates than those with a lower number of participants do. The requirement of Mühlemanns[46] for a minimum of 90 % follow-up examinations of the originally treated cases was exceeded though, as 100 % of the RER and 95.5 % of the TR teeth were rechecked.

One critical point is that the simplified Sargenti technique[37,38] was used for RCT. This technique entails the use of formaldehyde-containing N2, which is a matter of significant debate. Regarding the absence of canal irrigation, as postulated by Sargenti, Byström and Sundqvist[48] state that a significant reduction in the number of micro-organisms can be achieved without disinfecting irrigants. Baugh and Wallace[49] and Sjögren et al.[50] recommend a strong canal preparation to reduce canal infection.[50] According to Wu et al.,[51] reduction of AP to a histologically acceptable level cannot be achieved. Nair et al.[51] performed one-stage RCT in 18 teeth with AP. Thereafter, the root ends were resected and examined. Persistent micro-organisms were found in 16 (88 %) resections.

In response to the perception that only the conservative endodontic method can achieve a reduction of bacteria, Sargenti developed N2, which produces formaldehyde-containing gases that enter otherwise inaccessible side canals and tubules. Ørstavik et al.[53] concede that the sealer used is significant to the result of an endodontic treatment. The focus of the current study was the systematic use of TR after orthograde RF using N2, a procedure that Sargenti proposed for the reduction of appointments for RCT of necrotic teeth, compared with RER—which Sargenti considered obsolete.

Sargenti[37,38] supported PC with TR only for the removal of filling material in cases of massive overfilling. In the present study, PC was omitted in all TR cases. Periapical granulation tissue was left to heal without PC. From the point of view of numerous authors,[23–27] removal of the granulation tissue is not necessary.

This study was based on the hypothesis that RER and TR lead to the same success results regarding the healing process (clinically, radiographically) and survival rate independent of the x-rays. When starting treatment, AP was present in an equal number of the respective teeth subjected to each therapy (63.5 %). A differentiation regarding the size of the apical lesions clearly revealed that wider translucencies predominate in TR cases. Only the presence of a large lesion had an influence on the success result. At the end of treatment, 17 (32.7 %) RER roots exhibited a larger apical lesion. During the subsequent control phase, radiographic failure was diagnosed in five cases (29.4 %). The situation was similar for TR cases: 31 cases (47 %) of an initial larger periapical translucency were later followed by eight radiographic failures (25.8 %) and two clinical failures (acute exacerbations). These results are similar to the findings of Kojima et al.[54] In their study of 5,839 non-vital teeth, they report 71.5 % successful treatments after RCT of teeth with AP and 82 % without AP.

The initial periapical situation was of equal importance to failure in RER and TR. A statistical significance of $p = 0.003$ in RER and of $p = 0.043$ in TR was demonstrated for an AP lesion > 5 mm. The statistically significantly higher failure rate of TR treatment by assistants might be ascribed to the fact that all seven assistant failures for TR featured a large apical lesion at the beginning of treatment, whereas only three of the five failures for TRs performed by the practice owner had such a lesion. However, the literature mentions that the RCT success rate also depends on the practitioner's qualification. According to the systematic review by Ng et al.,[55] general dentists scored the worst, with a success rate of 65.7 %. The success rate of students was 74.8 % and 84.8 % for specialists.

Treatment	RER					TR					
Control	Post-RER		*n* = 52			Control	Post-TR		*n* = 63		
	Treated		Failed		*p*-value		Treated				*p*-value
Factor	*n*	%	*n*	%		**Factor**	*n*	%	*n*	%	
Treatment by					0.435	**Treatment by**					0.044
Author	37	71.2	5	13.5		Author	37	58.7	5	13.5	
Assistant	15	28.8	2	13.3		Assistant	26	41.3	7	26.9	
Age of patients					0.497	**Age of patients**					0.705
≤ 27	25	41.1	4	16.0		≤ 27	32	50.8	5	15.6	
28+	27	51.9	3	11.1		28+	31	49.2	7	22.6	
Sessions					0.779	**Sessions**					0.833
1	33	63.5	3	9.1		1	47	74.6	9	19.1	
> 1	19	36.5	4	21.1		> 1	16	25.4	3	18.7	
Location					0.440	**Location**					0.746
16/26	36	69.2	6	16.7		36/46	34	54	7	20.6	
Others	16	30.8	1	6.2		Others	29	46	5	17.2	
Initial diagnosis					0.003	**Initial diagnosis**					0.043
NAD at the apex	19	36.5	1	5.3		NAD at the apex	21	33.3	1	4.8	
Lesion < 5 mm	16	30.8	1	6.2		Lesion < 5 mm	11	17.5	1	9.1	
Lesion ≥ 5 mm	17	32.7	5	29.4		Lesion ≥ 5 mm	31	49.2	10	32.3	**Table 2**

Table 2_Failure of roots in relation to factors.

The importance of AP prior to RCT can be measured radiographically, but is also expressed in the survival rate. Dammaschke et al.[56] report that 64.1 % of teeth with initial AP survived 11 years after conservative RCT versus 83.6 % for teeth with no AP. In the present study, 52.2 % of the teeth with an AP lesion > 5 mm survived after 11 years regarding extraction frequency and 85.4 % of teeth with a different initial diagnosis. A similar difference was observed in the radiographic failure rate, which was diagnosed in 31.25 % of the 48 cases with an AP lesion > 5 mm after 11 years, whereas a therapy failure of 6 % was recorded for 67 teeth with a different initial diagnosis.

Teeth with necrotic pulp can be treated effectively in one appointment, as this study has proved—this applies also to teeth with pathology and AP: 26 (83.9 %) of the 31 TR cases with a larger lesion and ten (58.8 %) of the 17 corresponding RER cases were treated in one appointment only. In 1999, 34.4 % of participating US endodontists[57] stated in a poll that they treated necrotic teeth in one appointment. In a poll of German dentists[58] in 2010, only 7.34 % reported performing RF during the appointment for initial preparation. Ng et al.[59] proved that RCTs performed during one or several appointments result in nearly identical success, namely 77.2 % and 77.4 %, respectively, with strict stipulations, and 89.5 % and 85.5 %, respectively with less-strict stipulations.

While the periapex was curetted for all RER cases, this was not the case for TR, which is why the effect of overfilling on failure in TR cases compared with other RF levels could be investigated. Including the three acute cases, nine of the 12 failures were due to the 39 overfilled roots, the other three to the remaining 24 followed-up roots. Despite the high failure percentage of 23.1 % in overfilled roots compared with 12.5 % in non-overfilled roots, a statistically significant distance was not found ($p = 0.371$). This however suggests that a disadvantage of overfilling might be found in larger samples. Kojima et al.[54] found a success rate of 70.8 % after overfilling, and Ng et al.[59] report a success of 65.8 % according to strict criteria and of 74.5 % according to less-strict criteria. The latter concluded from a literature review that for RCT the mandibular molars had the lowest treatment success rates compared with all tooth types, whereas the maxillary molars had average success rates. Only molars were considered in the present study. Differences in the success of RCT in maxillary and mandibular molars could not be verified.

_Conclusion for the practice

For the practitioner, TR is technically easier and more time-saving than RER is because access to the periapex is sufficient. Both therapy alternatives have identical treatment successes and survival rates. PC performed with TR or RER is optional in cases of massive overfilling and can be disregarded for cases of slight overfilling. RER after orthograde RF of non-vital teeth is only indicated for a problem in the apical root section, such as too short RF or in case of "ferrum alienum"._

Editorial note: A complete list of references is available from the publisher.

Acknowledgements
Dr Ernst Goffart acted as second advisor for radiology diagnostics. Dr Tanja Kottmann performed the statistical analysis. I wish to thank both of them for their contributions.

_contact roots

Dr Robert Teeuwen
Berliner Ring 100
52511 Geilenkirchen
Germany

robteeuwen@t-online.de